

Dynamic Lumbosacral Radiograph in Comparison with Conventional Lumbosacral Radiograph in Finding Degenerative Disease of The Lumbar Spine

Fityay Adzhani¹, Muchtar Hanafi^{1*}, Amelia Tjandra Irawan^{1,2}, Hari Wujoso³

AFFILIATIONS

1. Radiology Department, Faculty of Medicine, Universitas Sebelas Maret
2. Musculoskeletal Subdivision, Dr. Moewardi General Hospital, Surakarta
3. Forensic Department, Dr. Moewardi General Hospital, Surakarta



This work is licensed under a Creative Commons Attribution-NonCommercial 4.0 International License.

ABSTRACT

Degenerative lumbar spine disease is a leading cause of disability, reducing patient's quality of life. However, Magnetic Resonance Imaging (MRI), the primary diagnostic modality, is not routinely feasible due to high cost and limited availability. Routine anteroposterior (AP) and lateral plain radiographs remain inferior to MRI, highlighting the need for alternative modalities such as vertebral dynamic radiography (flexion-extension views) to assess intervertebral instability. This analytic observational study used a cross-sectional design analyzing 42 patients at RSUD Dr. Moewardi (February 2019 - February 2020) with MRI-confirmed degenerative disease, the study compared findings of spondylolisthesis, vacuum disk phenomenon, osteophytes, and intervertebral space narrowing. Statistical analysis obtained p -value < 0.05 , demonstrating that dynamic radiographs possess higher sensitivity for detecting degenerative diseases of the spine than conventional views. Furthermore, the vacuum disk phenomenon was most prevalent in extension radiographs and least frequent in flexion. While osteophyte detection and intervertebral space narrowing remained consistent across both modalities, the dynamic study proved superior in assessing joint instability. The study concludes that there was a significant difference in the findings of spondylolisthesis on dynamic lateral radiographs and conventional lateral radiographs.

KEYWORDS:

Degenerative Disease, Spine, Dynamic Lumbosacral, Plain Radiograph

CORRESPONDING AUTHOR:
Muchtar Hanafi

muchtar.hanafi@staff.uns.ac.id

INTRODUCTION

Degenerative disease of the lumbar spine is an important and significant cause of disability (Astuti et al., 2025). This disease has a variety of symptoms, such as lower limb pain, limb weakness, and low back pain (LBP), which can reduce the quality of life. Low back pain is a disease with a prevalence of life time 70-85%. The Global Burden of Disease (GBD) study reported that LBP ranks the highest to cause disability, with 83 million incidents of disability in 2010. Degenerative diseases include spondylolisthesis, joint degeneration, and spinal stenosis. Disruption of the normal disc can cause retropulsion of the nucleus pulposus, which can

compress the spinal cord or nerve root causing radiating pain and limb weakness. More than 90% cases of disc herniation occur in the lumbosacral segment. The incidence of degenerative lumbar disease is 4.18 per 1000 population (Deane and McGregor, 2016; Ravindra et al., 2018; Modic and Ross, 2007; Zylbersztejn et al., 2012).

Radiological examination plays an important role in diagnosing degenerative diseases of the spine, especially with magnetic resonance imaging (MRI) which can provide a noninvasive evaluation of the vertebrae and spinal joints. However, MRI cannot be used as a routine check-up due to high costs and availability in health facilities. Meanwhile,

anteroposterior (AP) and lateral plain radiographs are routine examinations performed in assessing spinal degenerative diseases. However, this examination is still far from being compared to MRI. Therefore, other plain radiographs are needed which are expected to support the diagnosis, such as dynamic plain radiographs (flexion-extension) to visualize the instability of the intervertebral joints (Hiyama et al., 2019; Kim et al., 2018; Tannor, 2017).

In order to find out the difference between conventional and dynamic lumbosacral plain radiographs in finding degenerative disease of the lumbar spine we performed this study.

METHODS

We conducted an analytic observational study with a cross-sectional approach in patient with degenerative disc disease admitted to Dr. Moewardi General Hospital, Surakarta, Indonesia from February 2019 to February 2020. The data were taken from secondary data of radiology installation patients. The diagnosis of spinal degenerative disc disease was confirmed clinically and radiologically with lumbosacral MRI. We excluded patients with any other diseases, such as trauma, tumor, metastasis and surgical history. Forty-two patients included to this study underwent conventional as well as dynamic lumbosacral plain radiographs. This study had been approved ethically by Dr. Moewardi

Hospital Ethics Committee with registration number 322/II/HREC/2020.

MRI examination was performed with a 1.5-tesla (HDxt 1.5T, GE Healthcare) comprising T1 and T2-weighted image sagittal sequences focusing on T2-weighted image to diagnose the degenerative disease of the subjects, and to rule out any other diseases. Measurements of conventional and dynamic lumbosacral plain radiographs of the 8 subjects were made with digital measuring tools of PACS DICOM Viewer. Meanwhile, the other 34 subjects were reviewed from the picture of radiographs films.

Two radiologists with subspecialty in musculoskeletal and neuroradiology reviewed the conventional and dynamic lumbosacral plain radiographs. The presence of spondylolisthesis resembling the degenerative instability of intervertebral joint was recorded as the degree of listhesis. It was measured by the distance between posterior-inferior superior vertebrae and posterior-superior inferior vertebrae on the lateral projection lumbosacral plain radiographs, both conventional and dynamic. This distance was divided by the width of the superior endplate of the vertebral body underneath which showed the percentage value of the displacement.

Measurement of listhesis from two radiologist was calculated with interclass correlation coefficient (ICC) to test the reliability of the measurement. We

used paired t-test to evaluate the difference between conventional and dynamic radiograph lumbosacral if the data were normally distributed. Wilcoxon rank test was used if the data were not normally distributed. The statistical analysis was calculated using SPSS software, version 23.

RESULT AND DISCUSSION

In assessing conventional lateral lumbosacral plain radiographs, radiologist 1 obtained the mean value of spondylolisthesis was $6.99 \pm 7.53\%$, while radiologist 2 had mean value of $6.95 \pm 7.50\%$. ANOVA test comparing those outcomes found no significant difference findings on conventional lateral lumbosacral plain radiograph ($p = 0.093$) meaning it had excellent reliability ($ICC = 1.000$). The assessment of lumbosacral lateral flexion plain radiographs performed by radiologist 1 obtained mean value of spondylolisthesis was $13.64 \pm 8.32\%$, and radiologist 2 obtained mean value of spondylolisthesis was $13.64 \pm 8.30\%$. Lateral lumbosacral extension plain radiographs assessed by radiologist 1 and 2 had the mean values of spondylolisthesis of $8.78 \pm 6.77\%$, and $9.02 \pm 6.64\%$, respectively. The ANOVA test obtained a p-value = 0.972 and 0.340 ($p > 0.05$) for lateral lumbosacral flexion and extension plain radiographs, respectively, thus there was no significant difference with ICC values of 1.000 and 0.937 for lateral lumbosacral flexion and extension plain radiographs, respectively, demonstrating excellent reliability. (Koo and Li, 2016)

All of the subjects included in the study were between 40 and 58 years old, comprising 23 (55%) females and 19 (45%) males. Degenerative disease of the lumbar spine confirmed by MRI examination showed various degrees of severity based on Pfirrmann classification. According to this study, most of the degenerative patients were in grade 4 (64.3%), meanwhile the least patients were in grade 2 and grade 5 (2.4% respectively).

Table 1. The findings of spondylolisthesis based on conventional and dynamic lateral lumbosacral radiographs.

Spondylolisthesis	Conventional	Dynamic	
		Flexion	Extension
Yes	22	34	29
No	20	8	13
Total	42	42	42

This study assessed spondylolisthesis on conventional and dynamic lateral lumbosacral plain radiographs, as well as other features of degenerative disease of the lumbar spine. Flexion dynamic lateral radiographs found spondylolisthesis in 34 subjects, while extension dynamic lateral radiographs revealed spondylolisthesis in 29 subjects. Conventional lateral radiographs found spondylolisthesis in 22 subjects. Thus 12 subjects were detected spondylolisthesis on flexion dynamic lateral radiographs and 7 subjects were detected spondylolisthesis on extension dynamic lateral radiographs, but were not detected on conventional lateral radiographs (Table 1).

Table 2. The distribution of spondylolisthesis subjects based on discus intervertebral level

Level	N	%
L3-4	5	14.7%
L4-5	26	76.5%
L5-S1	3	8.8%
Total	34	100.0%

The distribution of intervertebral disc levels in 34 subjects with spondylolisthesis is shown in Table 2. Most of the degenerative subjects with spondylolisthesis were at the level of L4-5 (76.5%), followed by the level of L3-4 (14.7%) and L5-S1 level (8.8%).

Table 3. Other radiologic findings on conventional and dynamic lateral lumbosacral radiograph.

Findings	Ye	No
Osteophyte		
Conventional	42	0
Flexion	42	0
Extension	42	0
Narrowing of spinal joint		
Conventional	32	10
Flexion	32	10
Extension	32	10
Vacuum disk phenomenon		
Conventional	12	30
Flexion	5	37
Extension	15	27

The other findings of degenerative disease of the lumbar spine on plain radiographs were narrowing of the spinal joints, sclerotics and osteophytes in the vertebral body endplate, as well as the formation of the vacuum disk phenomenon. Both conventional and dynamic lateral radiograph (flexion and extension) revealed osteophytes in 42 subjects (100%) and narrowing of the spinal joint in 32 subjects (76.2%). Meanwhile the formation of vacuum disk phenomenon, was found most on lateral extension radiograph (N = 15; 35.7%), followed by lateral flexion radiograph (N = 5; 11.9%) (Table 3).

Table 4. The difference between conventional and dynamic flexion lateral lumbosacral radiograph in finding spondylolisthesis.

	Conventio nal (%)	Flexion (%)	p-value
Spondylolis thesis	6.99 ± 7.53	13.64± 8.32	<0.001*

Notes: Wilcoxon rank test, 5% level of significance

Wilcoxon rank test comparing conventional with lateral dynamic flexion lumbosacral plain radiographs in degenerative spondylolisthesis of the lumbar spine obtained p value of < 0.001 with the mean values of 6.99 ± 7.53% on conventional and 13.64 ± 8.32% on flexion lateral lumbosacral radiograph (Table 4). It means that degenerative spondylolisthesis was found more on lateral dynamic flexion radiograph, the statistical analysis showed significant differences.

Table 5. Difference between conventional and dynamic extension lateral lumbosacral radiographs in finding spondylolisthesis.

	Conventio nal (%)	Extension (%)	p-value
Spon dylolis thesis	6.99± 7.53	8.78± 6.77	0.035*

Notes: Wilcoxon rank test, 5% level of significance

The spondylolisthesis finding on conventional lateral lumbosacral radiograph and extension lateral lumbosacral radiograph obtained mean values of 6.99 ± 7.53% and 8.78 ± 6.77%, respectively (p = 0.032), which means that degenerative spondylolisthesis was found more on lateral dynamic extension radiograph, the statistical analysis showed significant differences (Table 5).

Degenerative disease of the spine is a spinal disease that occurs due to a degenerative process. Degenerative cascade process explains lumbar degeneration through three phases, namely dysfunction phase in the form of muscle stiffness leading to annular tears and cartilage degeneration causing disc material herniation as well as

dehydration of the disc so that it can form the vacuum disc phenomenon, the instability phase with laxity of the facet capsule laxity and disc disruption resulting in segmental instability causing degenerative spondylolisthesis, and the last phase is the stabilization phase by forming the osteophytes and thickening flavum ligament compressing the spinal canal. Therefore, the radiological image on the lateral plain radiograph shows the appearance of osteophytes on the edge of the vertebral body endplate, narrowing of the intervertebral space, vacuum disc phenomenon, and instability with degenerative spondylolisthesis. Meanwhile MRI examination can find degenerative spinal joints in the form of changes in the intensity of the disc, as well as in the ligament around the spine and compression of the spinal canal. (Garvin et al., 2018; Herring, 2016; Devlin, 2012)

In this study, we found differences in several findings obtained on conventional and dynamic lateral radiographs. These differences are spondylolisthesis and vacuum disk phenomenon. In addition, the intervertebral space narrowing and the osteophytes findings were similar on both conventional and dynamic lateral radiographs. The spondylolisthesis which was mostly found at the L4-5 level (76.5%) is in line with the theory of deformity and instability. The occurrence of instability due to degenerative changes can result in translation or spondylolisthesis, this condition occurs

more frequently at the L4-5 level, where the presence of the iliolumbar ligament at the L5 level limits the movement of L5, so that the L4-5 level becomes relatively easier to move. The more sagittal orientation of the facet joints at the L4-5 level is also an additional predisposing factor for instability at that level. (Garvin et al., 2018)

Anatomy of the spine based on Denis as shown in Figure 1, is divided into three compartments, anterior, media and posterior, in which degenerative disease of the spine starting from the intervertebral disc, which is the anterior and media structure changes, leading to spondylolisthesis caused by instability of the posterior compartment. This degenerative process also involves three joint complexes, the intervertebral disc and two facet joints. Initiation of degenerative processes is in the intervertebral discs. This can also be the basic findings of spondylolisthesis in degenerative patients which most commonly found on dynamic lateral radiograph (flexion), because in the flexion position, the facet joints seem to be moved away so the loose condition of facet joints (laxity) with instable condition of intervertebral disc will be easily visible as a spondylolisthesis. (Garvin et al., 2018; Devlin, 2012; Steinmetz and Benzel, 2016)

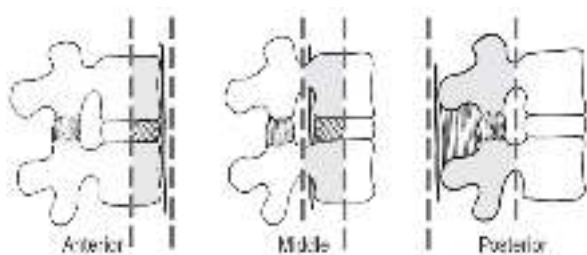


Figure 1. Anatomy of the spine based on Denis. (Devlin, 2012)

Treatment options for degenerative disease of the spine are non-surgical and surgical therapy. Surgical therapy comprises several surgical options according to clinical and radiological examinations. Spondylolisthesis which represents the degenerative instability can be an indicator of degenerative severity and a pain generator, thus it is a determining factor in choosing of surgery for degenerative patients of the spinal joints. (Garvin et al., 2018; Devlin, 2012)

Several previous studies comparing therapy with or without the combination of interbody fusion (either posterolateral or transforaminal lumbar) in cases of degenerative spondylolisthesis, found that the combination of interbody fusion therapy has a better prognosis and reduced the need for reoperation, as compared to therapy without the interbody fusion combination. A study by Dharma AS, et al in Surakarta also reported that the procedure of Posterior Lumbar Interbody Fusion (PLIF) on the management of lumbar spinal stenosis with instability showed better functional results. Spondylolisthesis is also an indication for Lumbar Total Disc Arthroplasty surgery. Therefore, the findings of spondylolisthesis on radiological

examinations that represent instability are important as these can influence the operator's decision in choosing the surgical option which can affect the patient's prognosis. (Garvin et al., 2018; (Devlin, 2012; Steinmetz and Benzel, 2016; Dharma et al., 2019)

In this study, we found that spondylolisthesis was mostly detected on flexion dynamic lateral radiographs with the average of 13.64% listhesis. Then followed by extension dynamic lateral radiographs in 29 patients and conventional lateral radiographs in 22 patients, with mean listhesis of 8.78% and 6.99%, respectively. The statistical analysis of our findings demonstrated a significant difference, in which spondylolisthesis indicating the presence of degenerative instability can be detected more through dynamic lateral radiographs (flexion and extension) than conventional lateral radiographs. Thus, dynamic lateral radiographs can affect decision in determining of treatment options for patients with degenerative spinal joints (Figure 2 and Figure 3).

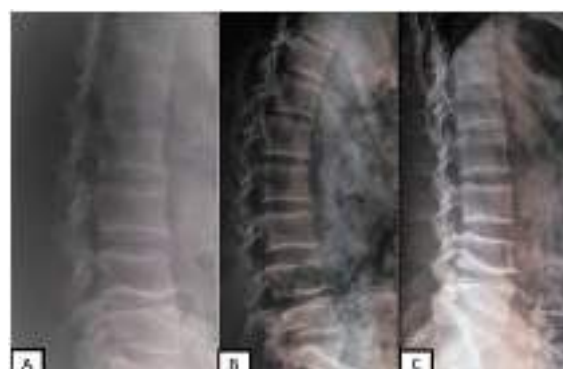

Figure 2. The conventional lateral radiograph of one of our samples (A) shows osteophytes in the vertebral body and there is no spondylolisthesis. On the flexion (B) and extension (C) lateral radiographs, there is posterolisthesis at the level of L4-5.

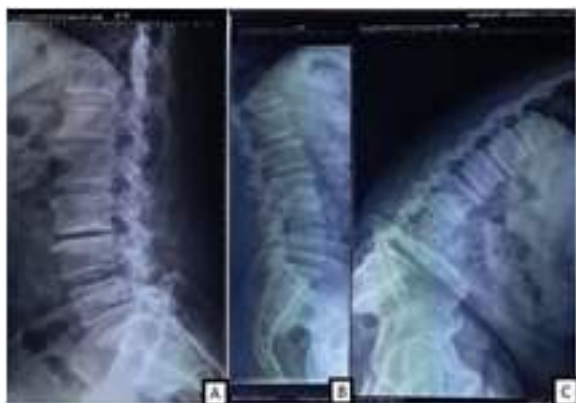

Figure 3. The conventional lateral radiograph of one of the study subjects (A) shows osteophytes and there is no spondylolisthesis. The extension lateral radiograph (B) demonstrates no spondylolisthesis, but the flexion lateral radiograph (C) reveals anterolisthesis at the level of L4-5.

Other findings of degenerative disease of the spine such as osteophytes and spinal joint narrowing on both conventional lateral and dynamic lateral (flexion and extension) lumbosacral radiographs were similar, in which osteophytes were found in all subjects (100%), and spinal joint narrowing were seen in 83.3% of subjects. However, another finding in the form of vacuum disc phenomenon was different. We found that vacuum disc phenomenon was more common on extension lateral radiographs (35.7%) than on conventional lateral radiograph (28.6%) and flexion lateral radiographs (11.9%).

Previous study by Kim CH, et al examining dynamic (flexion and extension) radiographs to predict the severity of spinal joint degeneration on MRI compared with conventional lateral radiographs reported that there was a significant correlation of the severity of spinal joint degeneration with extension dynamic plain radiographs as compared with conventional lateral radiographs. However, this study examined degenerative diseases of the

cervical spine, not the lumbosacral region. (Kim et al., 2018)

Study by Spina N, et al examining instability in degenerative spondylolisthesis based on the surgeon's point of view revealed that it was necessary to assess instability with the finding of spondylolisthesis on dynamic lateral radiographs, and the finding of spondylolisthesis on conventional lateral radiographs was not meaningful unless it was more than 4 mm. Previous study by Pieper CC, et al examining radiological evaluation of instability with lumbar spondylolisthesis, found that flexion dynamic lateral radiographs were significantly needed to assess spondylolisthesis compared to conventional lateral radiographs. However, extension dynamic lateral radiographs were not required because they were considered not significantly different from conventional lateral radiograph. (Spina et al., 2019; Pieper et al., 2014)

CONCLUSION

This study suggest that dynamic lateral radiograph examination is also required to diagnose degenerative disease of the lumbar spine because there are findings which may not be obtained from conventional lateral radiographs. Both dynamic lateral radiographs (flexion and extension) are important because they have significant differences to evaluate degenerative instability compared to conventional lateral radiographs, especially in the case of patients with degenerative lumbosacral joints. These findings can certainly be considered by clinicians to add dynamic lateral radiographs as a

package of examinations that must be carried out in patients with degenerative of the lumbar spine, whether MRI is available or not available because it can affect treatment decisions and patient's prognosis.

FUNDING

This study was fully funded independently and received no external financial support from public, commercial, or non-profit funding institution.

ACKNOWLEDGEMENT

The authors would like to express sincere gratitude to the Radiology Department of Dr. Moewardi General Hospital for the technical support provided throughout the research process.

REFERENCES

1. Astuti, N.A., Hanafi, M., Irawan A.T., Adhie, A.W. (2025) Patellar Height Examination With Various Methods On Genu X-Ray: In A Search Of The More Precise Combination, *Biomedika*, 17(2), hlm. 116-122.
2. Deane, J.A. dan McGregor, A.H. (2016) 'Current and future perspectives on lumbar degenerative disc disease: A UK survey exploring specialist multidisciplinary clinical opinion', *BMJ Open*, 6(9), hlm. 1-11.
3. Devlin, V.J. (2012) *Spine Secrets Plus*. Edisi ke-2. St. Louis, Missouri: Elsevier Mosby.
4. Dharma, A.S., Ermawan, R., Utomo, P. dan Handojo, H.T. (2019) 'Korelasi Fusion Rate terhadap Functional Outcome Pasien Lumbar Spinal Stenosis Pasca PLIF', *Biomedika*, 11(2), hlm. 61-67. doi: 10.23917/biomedika.v11i2.7613.
5. Garvin, S.R., Eismont, F.J., Bell, G.R., Fischgrund, J.S. dan Bono, C.M. (2018) *Rothman-Simeone and Herkowitz The Spine*. Edisi ke-7. Philadelphia: Elsevier.
6. Herring, W. (2016) *Learning Radiology: Recognizing the Basics*. Edisi ke-3. Philadelphia: Elsevier.
7. Hiyama, A., Katoh, H., Sakai, D., Tanaka, M., Sato, M. dan Watanabe, M. (2019) 'The correlation analysis between sagittal alignment and cross-sectional area of paraspinal muscle in patients with lumbar spinal stenosis and degenerative spondylolisthesis', *BMC Musculoskeletal Disorders*, 20(1), hlm. 1-9. doi: 10.1186/s12891-019-2733-7.
8. Kim, C.H., Hwang, J.M., Park, J.S., Han, S. dan Park, D. (2018) 'Predictability of severity of disc degeneration and disc protrusion using horizontal displacement of cervical dynamic radiographs: A retrospective comparison study with MRI', *Medicine (United States)*, 97(25), hlm. 0-7.
9. Koo, T.K. dan Li, M.Y. (2016) 'A Guideline of Selecting and Reporting Intraclass Correlation Coefficients for Reliability Research', *Journal of Chiropractic Medicine*, 15(2), hlm. 155-163. doi: 10.1016/j.jcm.2016.02.012.
10. Modic, M.T. dan Ross, J.S. (2007) 'Lumbar degenerative disk disease', *StatPearls Publishing*, 245(1), hlm. 43-61.
11. Pieper, C.C., Groetz, S.F., Nadal, J., Schild, H.H. dan Niggemann, P.D. (2014) 'Radiographic evaluation of ventral instability in lumbar spondylolisthesis: Do we need extension radiographs in routine exams?', *European Spine Journal*, 23(1), hlm. 96-101. doi: 10.1007/s00586-013-2932-0.
12. Ravindra, V.M., Senglaub, S.S., Rattani, A., et al. (2018) 'Degenerative Lumbar Spine Disease: Estimating Global Incidence and Worldwide Volume', *Global Spine Journal*, 8(8), hlm. 784-794.
13. Spina, N., Schoutens, C., Martin, B.I., Brodke, D.S., Lawrence, B. dan Spiker, W.R. (2019) 'Defining Instability in Degenerative Spondylolisthesis: Surgeon Views', *Clinical Spine Surgery*, 32(10), hlm. E434-E439. doi: 10.1097/BSD.0000000000000874.
14. Steinmetz, M.P. dan Benzel, E.C. (2016) *Benzel's Spine Surgery: Techniques, Complication Avoidance, and Management*. Edisi ke-4. Philadelphia: Elsevier. doi: 10.1017/CBO9781107415324.004.
15. Tannor, A.Y. (2017) 'Lumbar Spine X-Ray as a Standard Investigation for all Low back Pain in Ghana: Is It Evidence Based?', *Ghana Medical Journal*, 51(1), hlm. 24-29. doi: 10.4314/gmj.v51i1.5.
16. Zylbersztejn, S., De Freitas Spinelli, L., Rodrigues, N.R., et al. (2012) 'Degenerative stenosis of the lumbar spine', *Revista Brasileira de Ortopedia*, 47(3), hlm. 2